

Medial Malleolus

Lateral Malleolus

Belly
extensor digitorum brevis

Medial (tibial) aspect

Lateral (fibular) aspect

Hallux

5th toe

4th toe

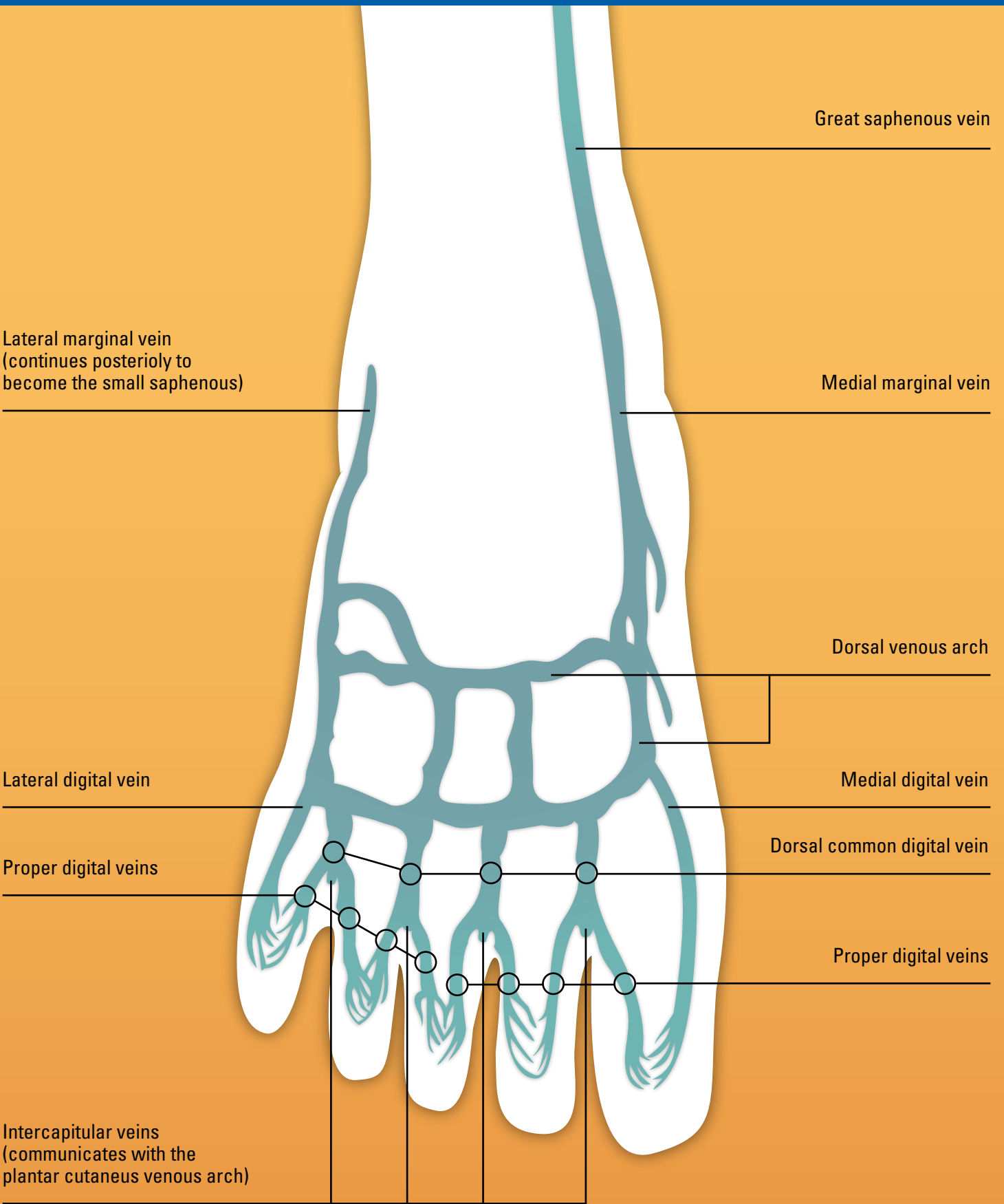
3th toe

2th toe

1th toe

1

DORSUM RIGHT FOOT



2

VENOUS SUPPLY DORSUM RIGHT FOOT